

# Preliminary Observations of Long Term Declaw Pathology

Ronald W Gaskin DVM

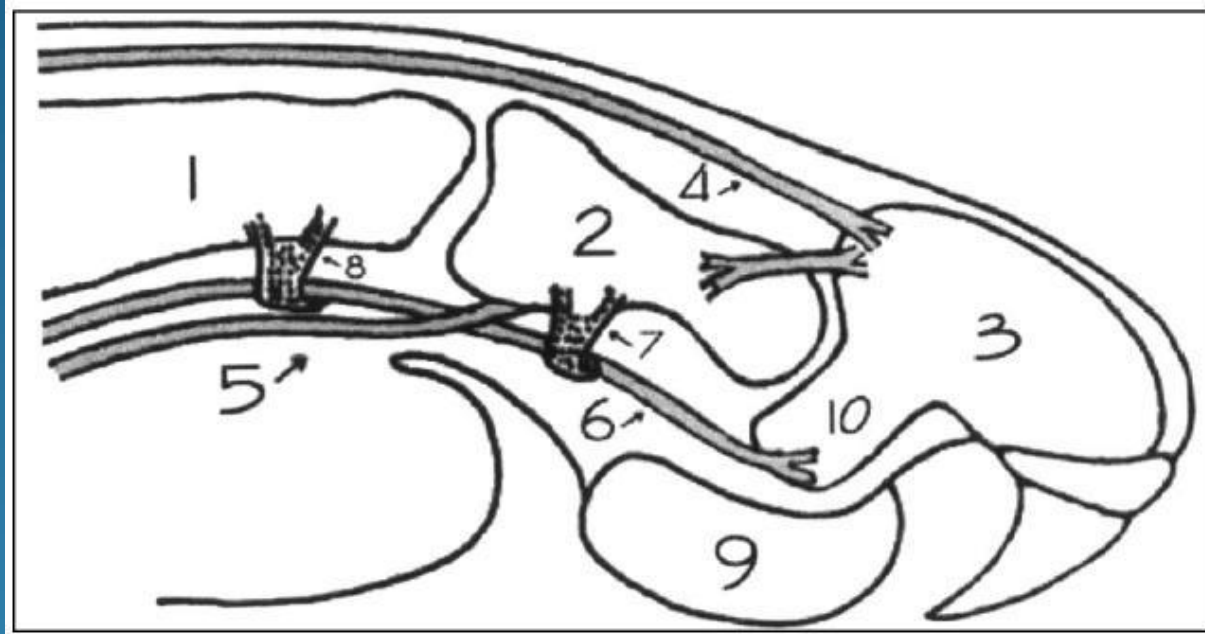
[www.msvets.com](http://www.msvets.com)

info@msvets.com

What happens 5-10 years after a front declaw is done



## Feline Paw Anatomy



Can. Vet. J.

2 - phalanx 2

5 - superficial flexor tendon

6 - deep flexor tendon

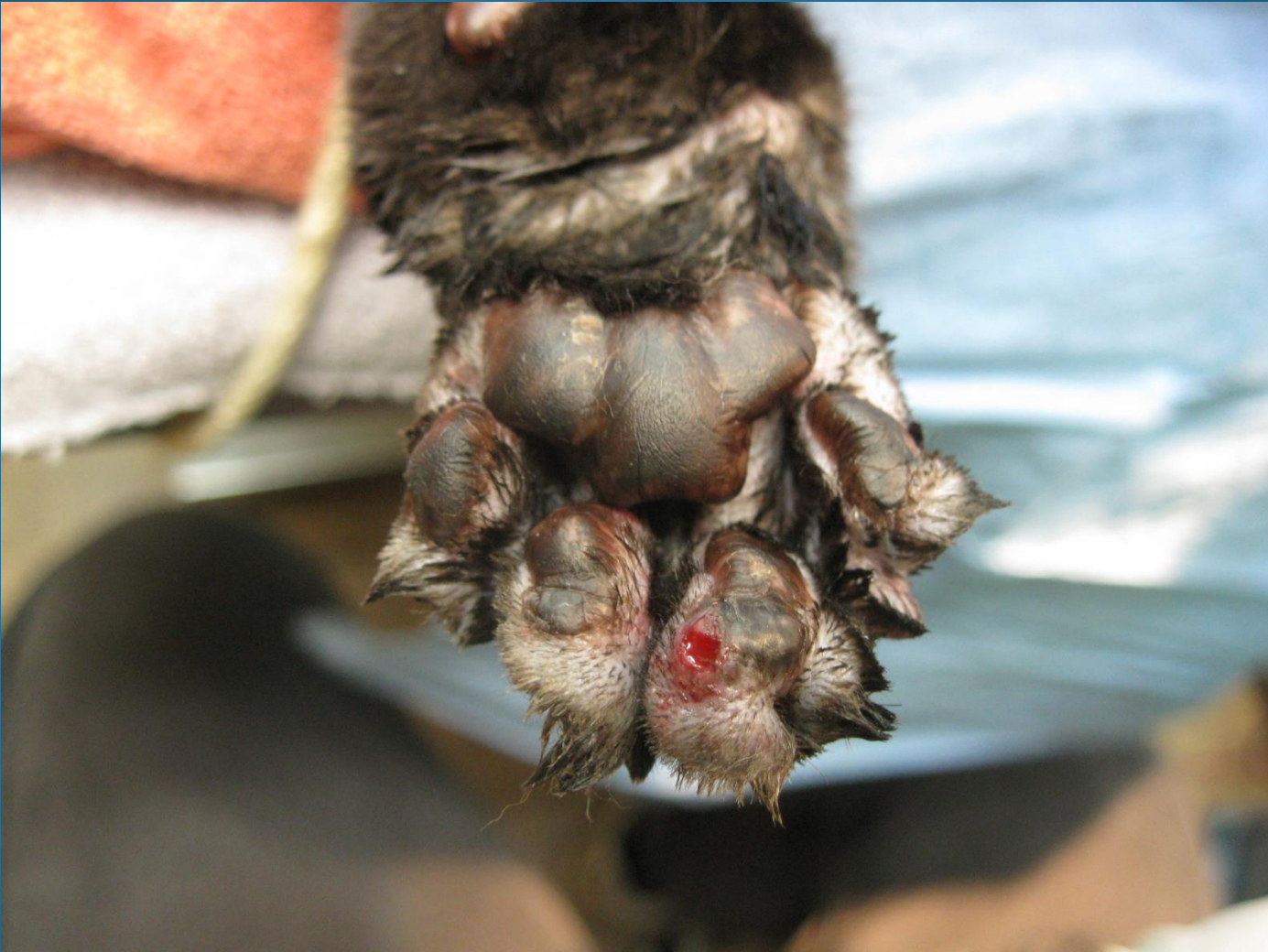## Patient History

- Inappropriate elimination.
- Holding either paw up.
- Limping
- Favoring weight on hind limbs
- Spotting blood on floor.
- Tight muscle knots in lumbar muscles.
- Pain or cramping in lower forearm muscles
- Running side ways.

## Examination

- Very reluctant to have digits straightened or even touched.
- Calluses on the front of digit pads especially digits 3 and 4.
- abscess present on front of digit or digit pad.
- Have to box the cat down to examine.

## Examination

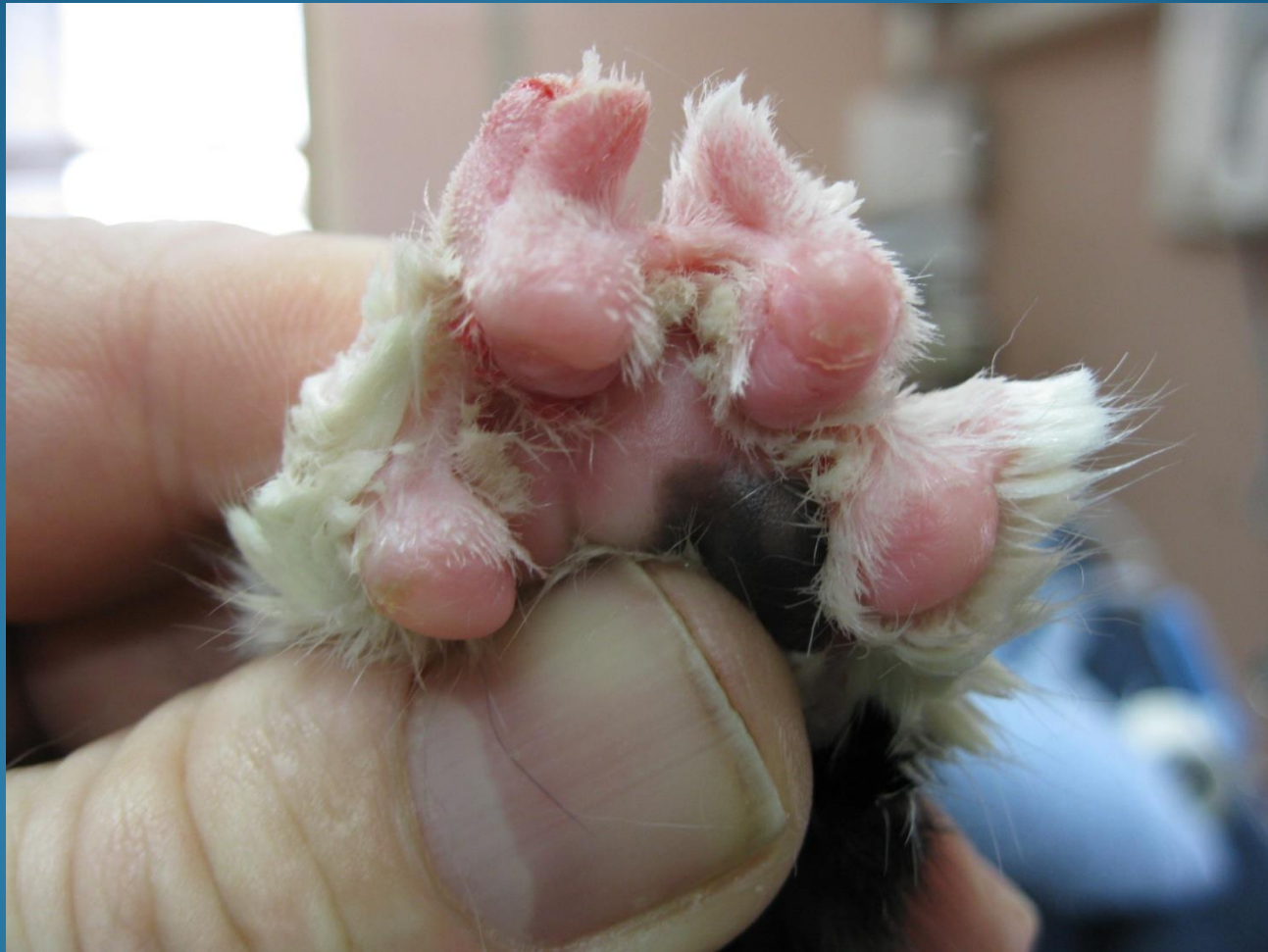



## Examination



## Examination



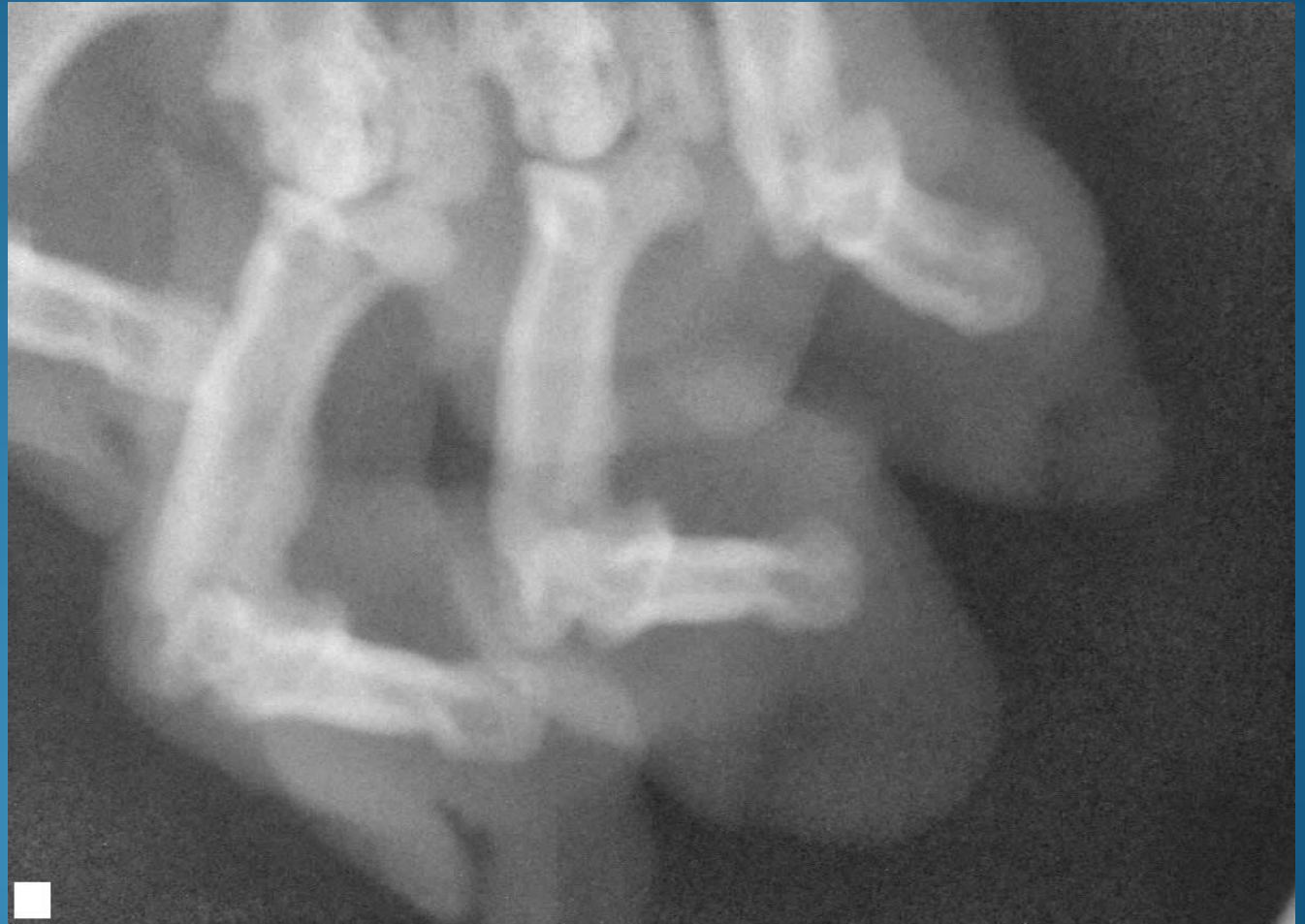

## Diagnostics

- \* Standard R/Os negative for inappropriate elimination.
  
- \* Under anesthesia
  - manually straightened digits snap back
  - flexor tendons in metacarpal area are very taut when digits are manually straightened.
  
- \* Radiographs (digital dental sensor size 1)
  - Use medial and lateral oblique dorsopalmar view
  - reveal distal P2 cartilage damage (Osteochondritis)
  - flexor tendonitis
  - P3 fragments

# Diagnostics

## Radiographs



## Declaw Salvage Surgery

### The prototype

Raven

7 year ,spayed, DM

Owner abandoned after DM dx

- Biting
- Attacking people.
- Inappropriate elimination

Placed in single cat home after  
4 weeks post surgery.



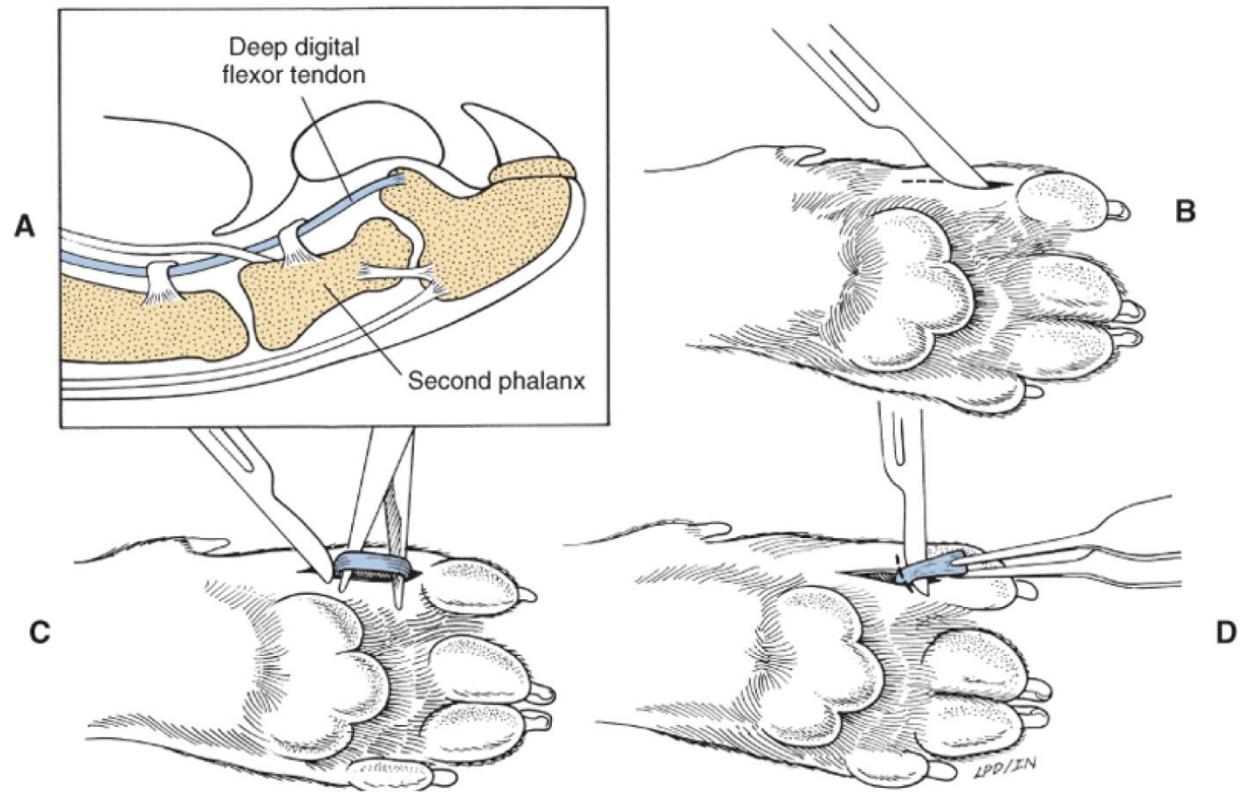
## Declaw Salvage Surgery

Flexor tenectomy  
deep & superficial  
RF scalpel used.

Positive response  
over all.

Negative flatfooted

Small Animal Surgery  
Fossum 3<sup>rd</sup> ed.



Copyright © 2007 by Mosby, Inc., an affiliate of Elsevier Inc.

Figure 15-57 Deep digital tenectomy. **A**, Make a 3- to 5-mm incision over the palmar surface of the second phalanx. **B** and **C**, Elevate and excise a 5-mm segment of deep digital flexor tendon. The inset shows the relationship of the deep digital flexor tendon to P1, P2, and P3.

## Recent California Declaw Legislation

California – has been the State to watch,

Los Angeles, San Francisco, Santa Monica, Beverly Hills, Berkeley, Culver City, and Burbank approved declaw bans.

West Hollywood passed the nation's first declaw ban in 2003

## Recent California Declaw Legislation

SB 762, Aaenstad. Professions and vocations: healing arts.

Existing law makes it unlawful for a city or county to prohibit a person, authorized by one of the agencies of the Department of Consumer Affairs to engage in a particular business, from engaging in that business, occupation, or profession or any portion thereof.

**This bill would also make it unlawful for a city, county, or city and county to prohibit a healing arts licensee from engaging in any act or performing any procedure that falls within the professionally recognized scope of practice of that licensee, but would prohibit** construing this provision to prohibit the enforcement of a local ordinance in effect prior to January 1, 2010, as specified, or to prohibit the adoption or enforcement of a local ordinance governing zoning, business licensing, or reasonable health and safety requirements, as specified.



## Recent California Declaw Legislation

Governor Schwarzenegger vetoes latest bill banning landlord forced declaw and debarking . Veto supported by the CVMA .

- 1) Possible step to State wide declaw ban bill.
- 2) Reason for Governor's veto “no evidence proving damage from declaw surgery.”

## Recent AVMA Declaw Policy changes (4/09)

“Declawing of domestic cats should be considered only after attempts have been made to prevent the cat from using its claws destructively or when its clawing presents a zoonotic risk for its owner(s).”

Possible dichotomy between AVMA declaw policy and MVMA membership declaw policy.

Minnesota veterinarians on declawing -  
19/20 MSVS Survey 2007

## Possible Minnesota Declaw Legislation?

Minnesota Agricultural subcommittees have retiring members.

A declaw ban bill could be on the floor within 4-5 years.

Large population passionate voters supporting a declaw ban in a liberal State. Client anger because inadequate Informed Consent prior to surgery and declaw outcome.

Major reason for failure of the declaw ban bill would be lack of strong evidence that there is damage occurring over the long term to declawed cats.

## References:

Bilateral flexor tendon contracture following onychectomy in 2 cats

Maureen A. Cooper, Peter H. Laverty, and Emily E. Soiderer

Can Vet J. 2005 March; 46(3): 244-246

<http://www.ncbi.nlm.nih.gov/pmc/articles/PMC1082868/>

## Acknowledgements:

Letrisa Miller MS DVM

Cat Clinic of Norman

Norman, Oklahoma



But I just asked him if he wanted to be declawed!

**Questions?**